

RESEARCH ARTICLE

Neuroprotective Effects of Clove Oil in Acrylamide Induced Neurotoxicity in Rats

Mohamed Aboubakr^{1*}, Samar Saber Ibrahim², Alshaimaa Mohamed Said³, Fatma Elgendey⁴ and Anis Anis⁵

¹Pharmacology Department; ²Forensic Medicine and Toxicology Department; ³Biochemistry Department; ⁴Animal Wealth Development Department, Faculty of Veterinary Medicine, Benha University, 13736 Moshtohor, Toukh, Qaliobiya, Egypt; ⁵Pathology Department, Faculty of Veterinary Medicine, University of Sadat City, Egypt

*Corresponding author: mohamed.aboubakr@fvtn.bu.edu.eg

ARTICLE HISTORY (18-331)

Received: September 02, 2018
Revised: October 07, 2018
Accepted: October 14, 2018
Published online: December 21, 2018

Key words:

Acrylamide
Clove oil
Hippocampus
Neurotoxicity
Protection
Rats

ABSTRACT

Clove oil (CO) is known for its antioxidant properties and has great potential for pharmaceutical, food, cosmetic and agricultural uses. Acrylamide (AA) as a potent neurotoxic agent and human exposure to AA involves dietary intake of carbohydrates processed at high temperature. This study evaluated if CO administration could protect against neurotoxicity induced by AA in rats. The rats were grouped into five groups, (I) control (corn oil), (II) AA (20 mg/kg BW), (III) CO (200 mg/kg BW), (IV) CO (100 mg/kg BW) in addition to AA (20 mg/kg BW) and (V) CO (200 mg/kg BW) in addition to AA (20 mg/kg BW). All treatments were administered for 21 days. AA produced oxidative stress and DNA damage in brain. The neuroprotective effects of CO which reverse the oxidative stress in rats treated with AA; increasing GSH, SOD and decreasing MDA levels. Moreover, it decreases the level of GABA, while it increases the AChE level returning all parameters towards normal levels. AA treatment induce a wide spread degeneration/necrosis in pyramidal neurons of CA3 region and neurons of granular layer (GL) of rat hippocampus. CO could minimize AA-induced neurotoxicity by attenuating oxidative brain injuries.

©2018 PVJ. All rights reserved

To Cite This Article: Aboubakr M, Ibrahim SS, Said AM, Elgendey F and Anis A, 2019. Neuroprotective effects of clove oil in acrylamide induced neurotoxicity in rats. Pak Vet J, 39(1): 111-115. <http://dx.doi.org/10.29261/pakvetj/2018.117>

INTRODUCTION

Acrylamide (AA) has received attention as a result of its neurotoxicity in animals and humans (Erkekoglu and Baydar, 2014). Diet is the main route of AA toxicity as AA is present in foods prepared at very high temperature such as fried potato, cookies and crackers (Xu *et al.*, 2014). Also, AA is an industrial pollutant; this chemical has been characterized as a carcinogen to animals and might create a risk to human health (Friedman, 2003).

Acrylamide acts as a neurotoxic agent. Genetic mutations and cellular transformation were occurred after high levels of AA (Park *et al.*, 2002). AA molecules could reach every organ and tissue in the body and reacts with DNA, neurons, hemoglobin (HB) and enzymes (Friedman, 2003).

The antioxidant activity and anti-inflammatory properties of clove (*Syzygium aromaticum*) essential oil made it one of the strongest essential oils (Chaieb *et al.*, 2007). CO had a different therapeutic activity starting from antioxidant to anticancer due to presence of eugenol which is a major component of CO, which reduced neurotoxicity (Matan *et al.*, 2006). It is safe, effective, inexpensive and effective anaesthetic for sedating fish (Jayakumar and Kanthimathi, 2012).

Therefore, the present study was conducted to investigate the neurotoxicity and DNA damage induced by AA in rats and the ameliorative effect of CO.

MATERIALS AND METHODS

Chemicals: AA was obtained from Sigma-Aldrich (USA) as a white powder (99% purity), while CO was obtained from El-Captain Company for extracting natural oils, herbs, and cosmetics, El-Obour City, Cairo, Egypt.

Experimental animals: Fifty adult male Wistar albino rats (185-210 g) were obtained from the laboratory animal's center, Faculty of Veterinary Medicine, Benha University, Egypt. Rats were kept in stainless steel cages and standard pellet diet and tap water *ad libitum* were provided. Ethical Committee Faculty of Veterinary Medicine, Benha University (IACUCREB), approved the study protocol.

Experimental design: Following 2 weeks of experimental acclimation, the rats were grouped into 5 groups (each of 10 rats). Group (I) were administered corn oil as vehicle. Group (II) AA were administered at a dose

of 20 mg/kg BW (Rahangadale *et al.*, 2012). Group (III) CO (200 mg/kg BW). Group (IV) CO (100 mg/kg BW) and AA (20 mg/kg BW). Group (V) CO (200 mg/kg BW) and AA (20 mg/kg BW). The doses of CO; 100 and 200 mg/kg BW (El-Hadary and Ramadan Hassanien, 2016). All treatments were given orally, once daily for 28 days. At the end of experiment, blood samples were collected through direct heart puncture for separation of serum which was kept at -20°C until biochemical analysis of AChE.

Measurement of serum AChE, brain GABA and brain lipid peroxidation and antioxidant status: Serum AChE activity was determined according to Ellman *et al.* (1961). Brain GABA content was measured by ELISA (Sutton and Simmonds, 1974). Glutathione (GSH) Superoxide dismutase (SOD) and Malondialdehyde (MDA) were estimated according to Beutler *et al.* (1963), Nishikimi *et al.* (1972) and Ohkawa *et al.* (1979), respectively.

Brain samples for comet assay: Brain from each rat in each group were immediately dissected out after scarification and put in ice cooled physiological saline 9% then prepared for Comet assay to estimate DNA damage parameters (Tail length, DNA in tail and tail moment) (Olive and Banath, 2006).

Histopathology: The brain of each rat was removed completely, the hippocampus was isolated and fixed in 10% formalin for 72h, washed, dehydrated, embedded in paraffin wax, serially sectioned with a microtome at 3µm thickness and stained with hematoxylin and eosin (H&E) for histopathological investigation.

Statistical analysis: Analysis were done by SPSS (24) software (SPSS Inc., Chicago, USA). The results were expressed as mean±SE using the analysis of variance test (one way ANOVA) followed by Duncan's multiple range test to determine the differences between the averages.

RESULTS

Effect of AA and/or CO on serum AChE and brain GABA: Table 1; showed, significant increase in brain GABA concentration after AA administration (101.27±1.60) as compared to control group (69.82±1.64). While co-administration of CO in both low (93.95±1.98) and high doses with AA (81.01±1.91), produced significant

decrease in brain GABA concentration when compared to AA treated group (Table 1). Serum AChE activity was significantly decreased in AA treated group (32.99±1.88) as compared to control group (92.83±1.53). While co-administration of CO in both low (54.30±2.04) and high doses with AA (76.17±3.17), significantly increased serum AChE activity when compared to AA treated group.

Brain lipid peroxidation and antioxidant status: AA administration at a dose of 20 mg/kg in rats significantly increased the oxidative stress marker MDA (8.71±0.52) when compared to the control group (4.18±0.23). Furthermore, AA significantly reduced brain antioxidant capacity as indicated by declines in GSH (0.88±0.07) and SOD levels (31.47±2.10) when compared to the control group (4.23±0.21 and 70.67±4.78), respectively as reported in Table 1. CO administration restored the antioxidant capacity in the 4th and 5th groups of rat's brains towards the normal capacity.

Comet assay of brain samples: As shown in Table (2) in AA treated group, tail length, DNA in tail%, and tail moment were significantly increased (14.44±1.06; 9.90±0.86 and 0.82±0.08) compared with control (6.46±0.29; 7.14±0.70 and 0.49±0.04) and CO treated groups (6.51±0.26; 6.98±0.68 and 0.50±0.06), respectively. These elevations were decreased in other treated groups with AA in combination with CO.

Histopathological changes in hippocampus: AA treatment induced a wide spread degeneration/necrosis in pyramidal neurons of CA3 region of rat hippocampus as well as perineuronal edema (Fig. 3B). In the other hand, AA treatment with both low and high doses of CO induced degeneration/ necrosis in a few and sporadic pyramidal neurons of CA3 region of hippocampus (Figure 4B and C respectively). No pathological changes can be observed in both negative control group (Fig. 3A) and CO treated group (Fig. 4A).

AA treatment induced a wide spread degeneration/ necrosis in neurons of granular layer (GL) of rat hippocampus (Fig. 5B). AA treatment with both low and high doses of CO induced degeneration/ necrosis in a few and sporadic neurons of granular layer of hippocampus (Fig. 6B and C respectively). No pathological changes can be observed in both negative control group (Fig. 5A) and CO treated group (Fig. 6A).

Table 1: Effect of AA and/or CO on serum AChE (U/L), brain GABA (µg/g) and brain antioxidant biomarkers [MDA (nmol/g), SOD (U/g) and GSH (mg/g)] in rats (n=10)

Groups	AChE (U/L)	GABA (µg/g)	MDA (nmol/g)	SOD (U/g)	GSH (mg/g)
I	92.83±1.53 ^a	69.82±1.64 ^d	4.18±0.23 ^d	70.67±4.78 ^a	4.23±0.21 ^a
II	32.99±1.88 ^d	101.27±1.60 ^a	8.71±0.52 ^a	31.47±2.10 ^d	0.88±0.07 ^d
III	94.09±1.08 ^a	70.55±1.68 ^d	4.06±0.13 ^d	73.71±3.84 ^a	4.10±0.18 ^a
IV	54.30±2.04 ^c	93.95±1.98 ^b	6.73±0.33 ^b	43.80±1.88 ^c	2.18±0.19 ^c
V	76.17±3.17 ^b	81.01±1.91 ^c	5.80±0.30 ^c	56.61±3.28 ^b	3.34±0.17 ^b

Values are mean±SE; Means with different alphabets as superscripts differ significantly (P<0.05); Group (I); control. Group (II); AA treated group. Group (III); Co treated group. Group (IV); AA and CO (100 mg) treated group. Group (V); AA and CO (200 mg) treated group.

Table 2: Comet assay (DNA damage) in control, AA and/or CO treated groups

Groups	Comet (%)	Tail length (PX)	DNA in tail (%)	Tail moment
I	15.82±1.43 ^b	6.46±0.29 ^c	7.14±0.70 ^b	0.49±0.04 ^b
II	25.40±1.51 ^a	14.44±1.06 ^a	9.90±0.86 ^a	0.82±0.08 ^a
III	13.06±1.28 ^b	6.51±0.26 ^c	6.98±0.68 ^b	0.50±0.06 ^b
IV	22.94±2.19 ^{ab}	9.53±0.82 ^b	8.70±0.66 ^{ab}	0.79±0.03 ^a
V	17.73±1.64 ^{ab}	9.43±0.83 ^b	7.98±0.74 ^{ab}	0.66±0.05 ^{ab}

Values are mean±SE; Means with different alphabets as superscripts differ significantly (P<0.05); Group (I); control. Group (II); AA treated group. Group (III); Co treated group. Group (IV); AA and CO (100 mg) treated group. Group (V); AA and CO (200 mg) treated group.

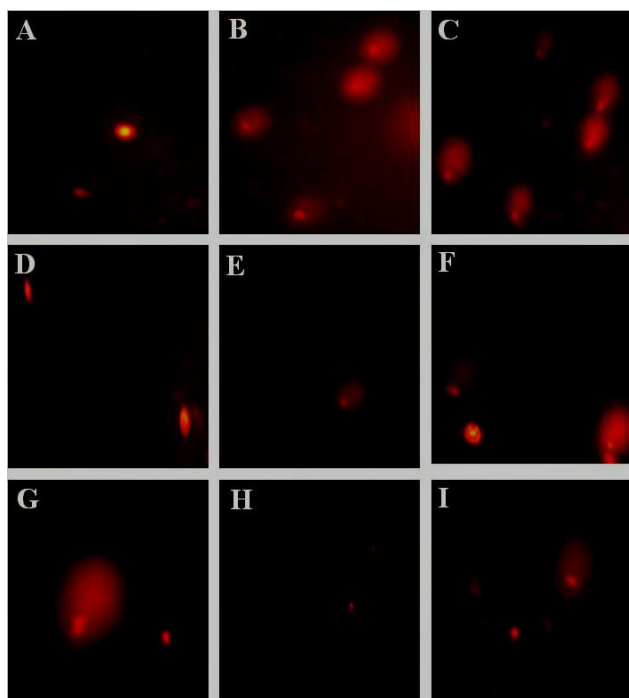


Fig. 1: Comet assay of brain samples: A; control. B,C; AA treated group. D,E; Co treated group. F,G; AA and CO (100 mg) treated group. H,I; AA and CO (200 mg) treated group.

DISCUSSION

Low antioxidant content and high oxygen consumption in the brain makes it the most sensitive organ to oxidative stress (Samarghandian *et al.*, 2017). AA acts as a neurotoxic agent in both humans and laboratory animals (Uthra *et al.*, 2017).

Reactive oxygen species (ROS) caused antioxidant stress and DNA damage. Antioxidant systems, including SOD, MDA and GSH, protect DNA from oxidative damage. Also, antioxidants in foods protect DNA and increases resistance against oxidative stress (Jayakumar and Kanthimathi, 2012). Oxidative stress was the main cause of neurotoxicity of AA (Mehri *et al.*, 2012).

The results showed that AA induced oxidative injuries in the brain and confirmed the intracellular lipid peroxidation (increased brain MDA concentrations) (Badgujar *et al.*, 2015). SOD and GSH were the first defense line against oxidative breakdown (Gill and Dumka, 2016). CO is enriched with many antioxidant ingredients which ameliorated the oxidative stress (Ogata *et al.*, 2000). Effects of the oxidative stress induced by AA were shown by elevated MDA concentration and reduced activity of antioxidant biomarkers GSH and SOD. Administration of AA increases lipid peroxidation and changed antioxidant enzymes system in brain of animals (Esmaeelpanah *et al.*, 2018). AA bind with GSH to create glycidamide, which is a genotoxic and carcinogenic substance leading to accumulation of free radicals, superoxide, nitric oxide (NO) and hydroxyl radicals (Klaunig, 2008).

Oxidative stress has been concerned in mutation and cancer development (Uthra *et al.*, 2017). Genotoxicity mainly occurred indirectly as a result of oxidative stress. Glycidamide was a mutagenic metabolite of AA which has a potent genotoxic agent. AA induced DNA damage and oxidative changes in rat brain due to the high-affinity of glycinamide to form DNA adducts (Alturfan *et al.*, 2012).

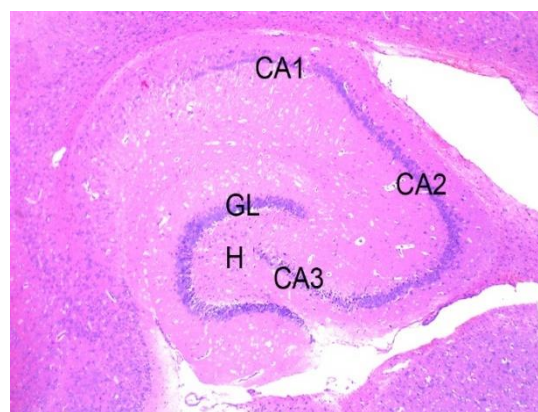


Fig. 2: Hippocampus; Rat; Control group, panoramic view: CA1, CA1 pyramidal layer; CA2, CA2 pyramidal layer; CA3, CA3 pyramidal layer; H, hilus; GL, granular layer. HE stain, Lieca EZ4 D stereomicroscope.

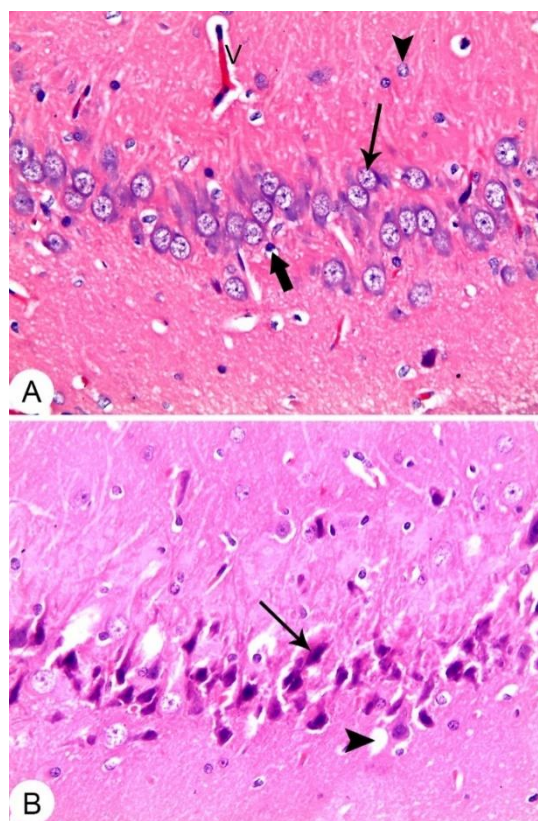


Fig. 3: CA3 region, Hippocampus, Rat. A) CO treated group: Showing normal histological architecture; Pyramidal cells (arrow). B) AA and CO (100mg) treated group: showing degeneration/ necrosis of sporadic pyramidal neuron (arrow). C) AA and CO (200mg) treated group: showing degeneration/ necrosis of sporadic pyramidal neuron (arrows). HE stain, X 20.

CO has anti-genotoxicity effect due to eugenol and provided protection against lipid peroxidation (Sharma *et al.*, 2011). The phenolic constituents of clove showed significant DNA protection due to its antioxidant properties and shown therapeutic potential including cyto-protective and DNA protective properties (Jayakumar and Kanthimathi, 2012). CO is known for its antioxidant characteristics. CO affected both cholinergic, glutamatergic systems and directly inhibits the NMDA induced cell neurotoxicity (Ogata *et al.*, 2000). Improvement of oxidative stress parameters in brain by clove treatment was confirmed by previous reports in rats (Jayakumar and Kanthimathi, 2012).

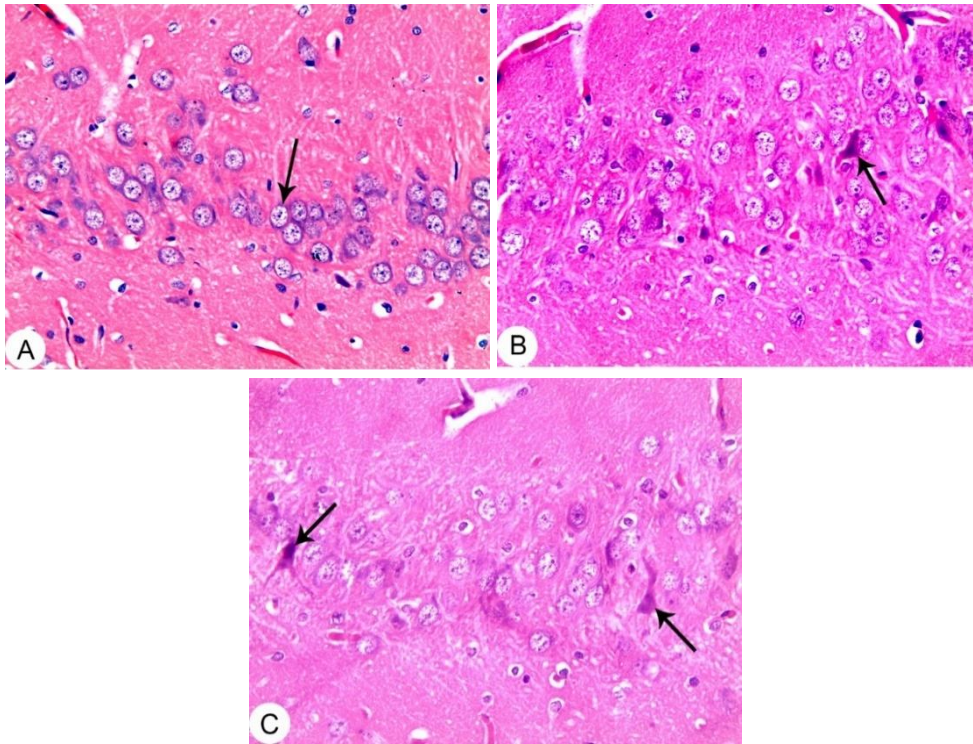


Fig. 4: CA3 region, Hippocampus, Rat. A) CO treated group: Showing normal histological architecture; Pyramidal cells (arrow). B) AA and CO (100mg) treated group: showing degeneration / necrosis of sporadic pyramidal neuron (arrow). C) AA and CO (200mg) treated group: showing degeneration / necrosis of sporadic pyramidal neuron (arrows). HE stain, X 20.

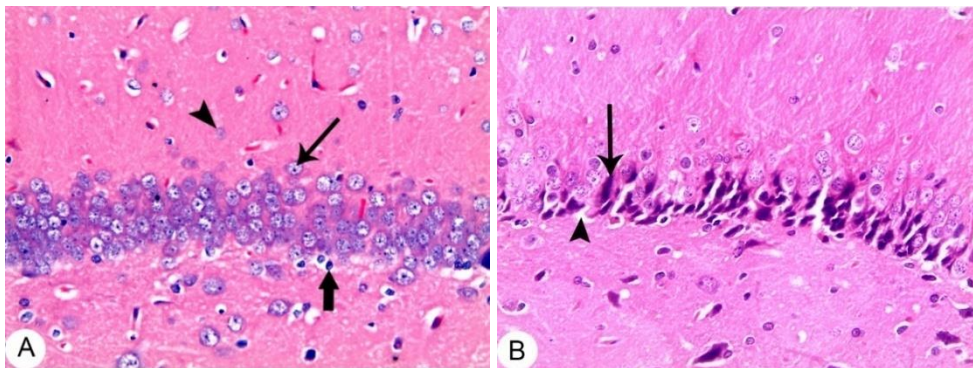


Fig. 5: Hippocampus; Rat, neurons of granular layer (GL): A), control group: Normal histological architecture. Granular neurons (thin arrow); Oligodendrocyte (thick arrow); astrocyte (arrowhead); B) AA treated group: showing wide spread degeneration/ necrosis in granular neurons (arrow) and perineuronal edema (arrowhead). HE stain, X 20.

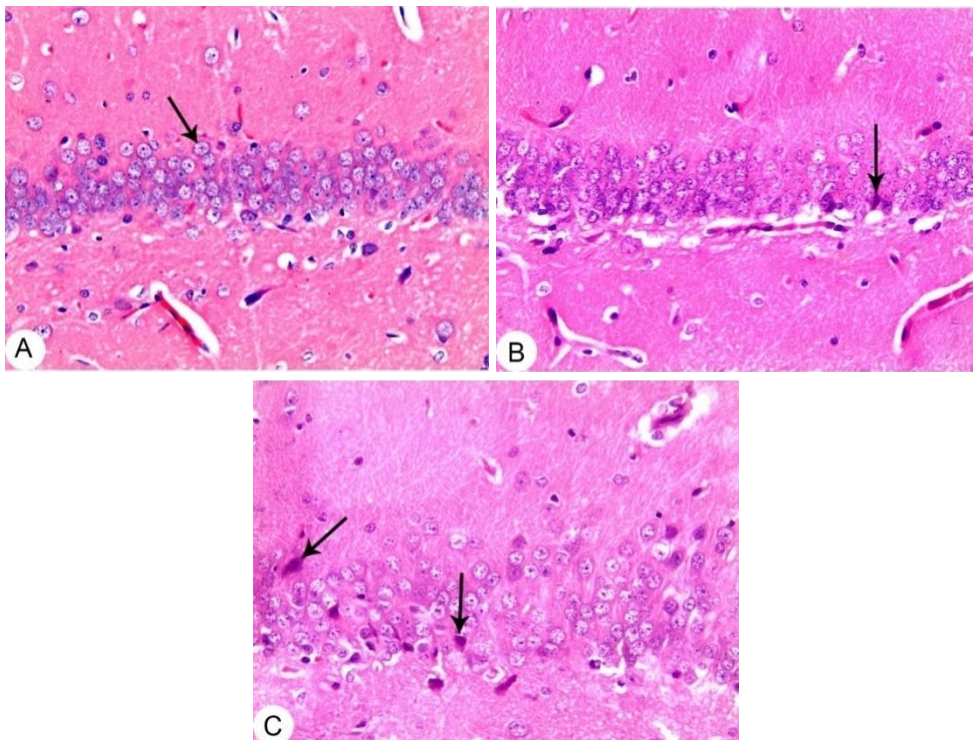


Fig. 6: Hippocampus; Rat, neurons of granular layer (GL): A) CO treated group: Showing normal histological architecture; granular neurons (arrow). B) AA and CO (100mg) treated group: showing degeneration/ necrosis of sporadic granular neurons (arrow). C) AA and CO (200mg) treated group: showing degeneration / necrosis of sporadic granular neurons (arrows). HE stain, X 20.

Acetylcholine (ACh); an excitatory neurotransmitter and Acetylcholinesterase (AChE) is associated with neuronal damage and brain development (Zimmerman and Soreq, 2006). Neurotoxicity induced by AA was confirmed by decreased AChE activity (Uthra *et al.*, 2017). This decrease was a result of inhibition of anterograde transport of AChE (Lopachin and Gavin, 2008). Administration of CO significantly recovered the AChE activity towards normal values as a result of its neuroprotective action (Jayakumar and Kanthimathi, 2012). After CO therapy, the improvement in the histopathology of brain also supported these results.

GABA is one of the most important inhibitory neurotransmitters in the CNS; low GABA level in the brain created several neurological disorders and high level of GABA produced synaptic depression and neuronal damage (Tian *et al.*, 2015). In this study, brain GABA level was increased after AA treatment compared to control group. An increase in expression of GABA was occurred due to toxic effect of AA (Tian *et al.*, 2015).

Histopathologically, AA toxicity in rats induced atrophy and nuclear pyknosis in some hippocampal neuronal cells (Mehri *et al.*, 2015; Mansour *et al.*, 2017). In this study, AA treatment induced a widespread neuronal injury in hippocampal neurons in CA3 region and granular layer. Co-administration with CO attenuates the neurotoxic effects of AA and this may be attributed to the neuroprotective role of CO through increasing the antioxidant activity, decreasing the oxidative stress and normalizing the AChE and GABA levels.

Conclusions: Oxidative stress plays a major role in AA-induced neurotoxicity. CO is potent antioxidants, which ameliorated the AA-induced neurotoxicity in rats, probably through enhancing tissue antioxidant defenses.

Authors contribution: All authors contributed equally in study (design, experimental work, analyzed the sera and tissue samples, statistical analysis, writing the manuscript). All authors interpreted the data, critically revised the manuscript for important intellectual contents and approved the final version.

REFERENCES

- Alturfan AA, Tozan-Beceran A, Sehirli AO, *et al.*, 2012. Resveratrol ameliorates oxidative DNA damage and protects against acrylamide-induced oxidative stress in rats. *Mol Biol Rep* 39:4589-96.
- Badgajar PC, Pawar NN, Chandratre GA, *et al.*, 2015. Fipronil induced oxidative stress in kidney and brain of mice: protective effect of vitamin E and vitamin C. *Pestic Biochem Physiol* 118:10-8.
- Beutler E, Duron O and Kelly BM, 1963. Improved method for the determination of blood glutathione. *J Lab Clin Med* 61:882-8.
- Chaieb K, Hajlaoui H, Zmantar T, *et al.*, 2007. The chemical composition and biological activity of clove essential oil, *Eugenia caryophyllata* (*Syzygium aromaticum* L. Myrtaceae): a short review. *Phytother Res* 21:501-6.
- El-Hadary AE and Ramadan Hassanien MF, 2016. Hepatoprotective effect of cold-pressed *Syzygium aromaticum* oil against carbon tetrachloride (CCl₄)-induced hepatotoxicity in rats. *Pharm Biol* 54:1364-72.
- Ellman GL, Courtney KD, Andres V, *et al.*, 1961. A new and rapid colorimetric determination of acetylcholinesterase activity. *Biochem Pharmacol* 7:88-95.
- Erkekoglu P and Baydar T, 2014. Acrylamide neurotoxicity. *Nutr Neurosci* 17:49-57.
- Esmaelpanah E, Razavi BM, Vahdati-Hasani F, *et al.*, 2018. Evaluation of epigallocatechin gallate and epicatechin gallate effects on acrylamide-induced neurotoxicity in rats and cytotoxicity in PC 12 cells. *Drug Chem Toxicol* 44:441-8.
- Friedman M, 2003. Chemistry, biochemistry, and safety of acrylamide. A review. *J Agric Food Chem* 51:4504-26.
- Gill KK and Dumka VK, 2016. Antioxidant status in oral subchronic toxicity of fipronil and fluoride co-exposure in buffalo calves. *Toxicol Ind Health* 32:251-9.
- Jayakumar R and Kanthimathi MS, 2012. Dietary spices protect against hydrogen peroxide-induced DNA damage and inhibit nicotine-induced cancer cell migration. *Food Chem* 134:1580-4.
- Klaunig JE, 2008. Acrylamide carcinogenicity. *J Agric Food Chem* 56:5984-88.
- Lopachin RM and Gavin T, 2008. Acrylamide-induced nerve terminal damage: relevance to neurotoxic and neurodegenerative mechanisms. *J Agric Food Chem* 56:5994-6003.
- Mansour SZ, Moawed FSM and Elmarkaby SM, 2017. Protective effect of 5, 7-dihydroxyflavone on brain of rats exposed to acrylamide or gamma-radiation. *J Photochem Photobiol B* 175:149-55.
- Matan N, Rimkeeree H and Mawson AJ, 2006. Antimicrobial activity of cinnamon and clove oils under modified atmosphere conditions. *Int J Food Microbiol* 107:180-5.
- Mehri S, Abnous K and Mousavi SH, 2012. Neuroprotective effect of crocin on acrylamide-induced cytotoxicity in PC12 cells. *Cell Mol Neurobiol* 32:227-35.
- Mehri S, Meshki MA and Hosseinzadeh H, 2015. Linalool as a neuroprotective agent against acrylamide-induced neurotoxicity in Wistar rats. *Drug Chem Toxicol* 38:162-6.
- Nishikimi M, Appaji N and Yagi K, 1972. The occurrence of superoxide anion in the reaction of reduced phenazine methosulfate and molecular oxygen. *Biochem Biophys Res Commun* 46:849-54.
- Ogata M, Hoshi M, Urano S, *et al.*, 2000. Antioxidant activity of eugenol and related monomeric and dimeric compounds. *Chem Pharm Bull*, 48:1467-9.
- Ohkawa H, Ohishi N and Yagi K, 1979. Assay for lipid peroxides in animal tissues by thiobarbituric acid reaction. *Anal Biochem* 95:351-8.
- Olive PL and Banath JP, 2006. The comet assay: a method to measure DNA damage in individual cells. *Nat Protoc* 1:23-9.
- Park J, Kamendulis LM, Friedman MA, *et al.*, 2002. Acrylamide-induced cellular transformation. *Toxicol Sci* 65:177-83.
- Rahagadale S, Jangir BL, Patil M, *et al.*, 2012. Evaluation of protective effect of vitamin E on acrylamide induced testicular toxicity in wistar rats. *Toxicol Int* 19:158-61.
- Samarghandian S, Samini F, Azimi-Nezhad M, *et al.*, 2017. Anti-oxidative effects of safranal on immobilization-induced oxidative damage in rat brain. *Neurosci Lett* 659:26-32.
- Sharma A, Kumar M and Kaur S, 2011. Modulatory effects of *Syzygium aromaticum* (L.) Merr. and Perry and *Cinnamomum tamala* Nees and Ebrem. on toxicity induced by chromium trioxide. *Phytopharmacology* 1:71-81.
- Sutton I and Simmonds MA, 1974. Effects of acute and chronic pentobarbitone on the gamma-aminobutyric acid system in rat brain. *Biochem Pharmacol* 23:1801-8.
- Tian SM, Ma YX, Shi J, *et al.*, 2015. Acrylamide neurotoxicity on the cerebrum of weaning rats. *Neural Regen Res* 10:938-43.
- Uthra C, Shrivastava S, Jaswal A, *et al.*, 2017. Therapeutic potential of quercetin against acrylamide induced toxicity in rats. *Biomed Pharmacother* 86:705-14.
- Xu Y, Cui B, Ran R, *et al.*, 2014. Risk assessment, formation, and mitigation of dietary acrylamide: current status and future prospects. *Food Chem Toxicol* 69:1-12.
- Zimmerman G and Soreq H, 2006. Termination and beyond: acetylcholinesterase as a modulator of synaptic transmission. *Cell Tissue Res* 326:655-69.